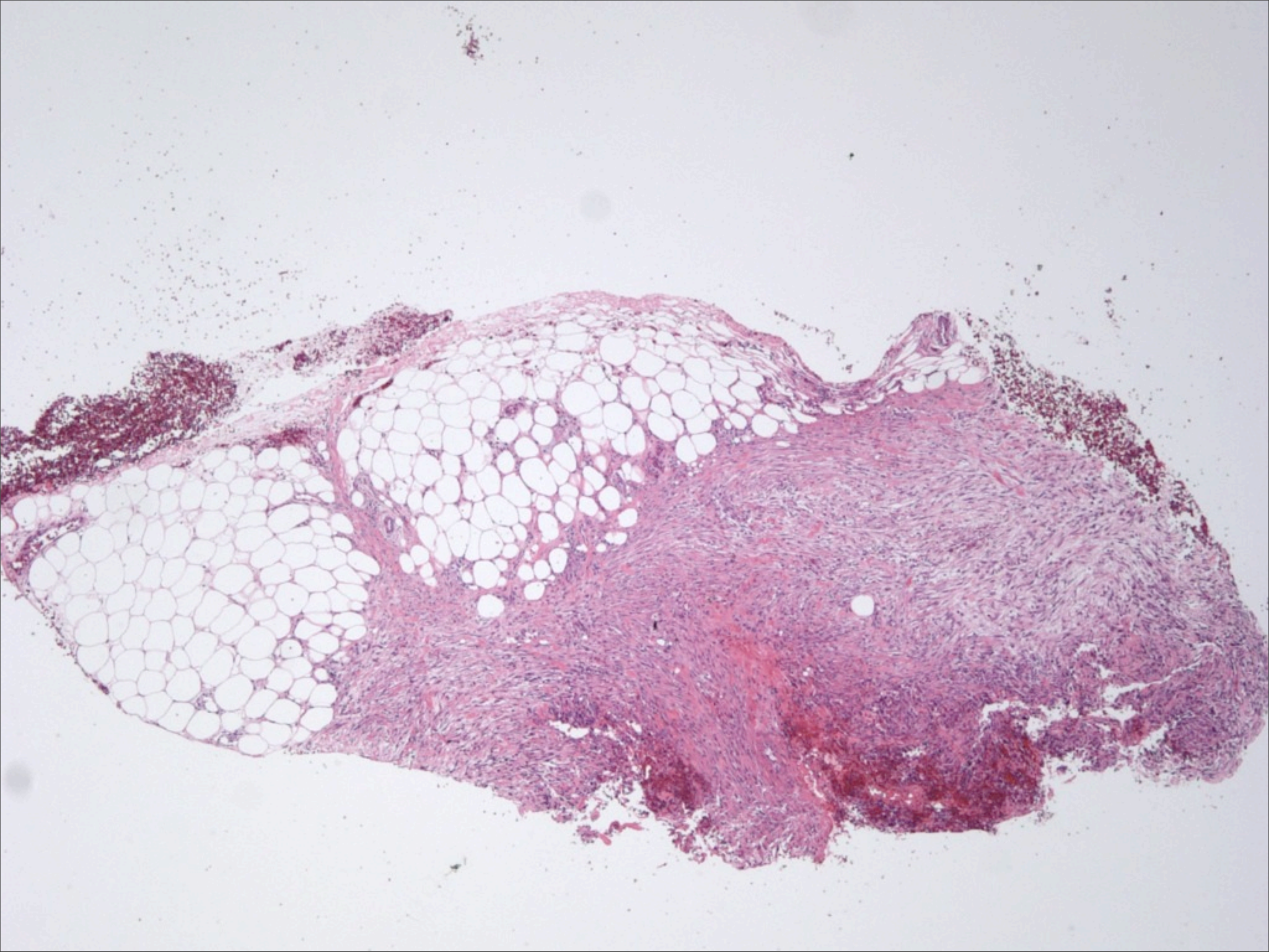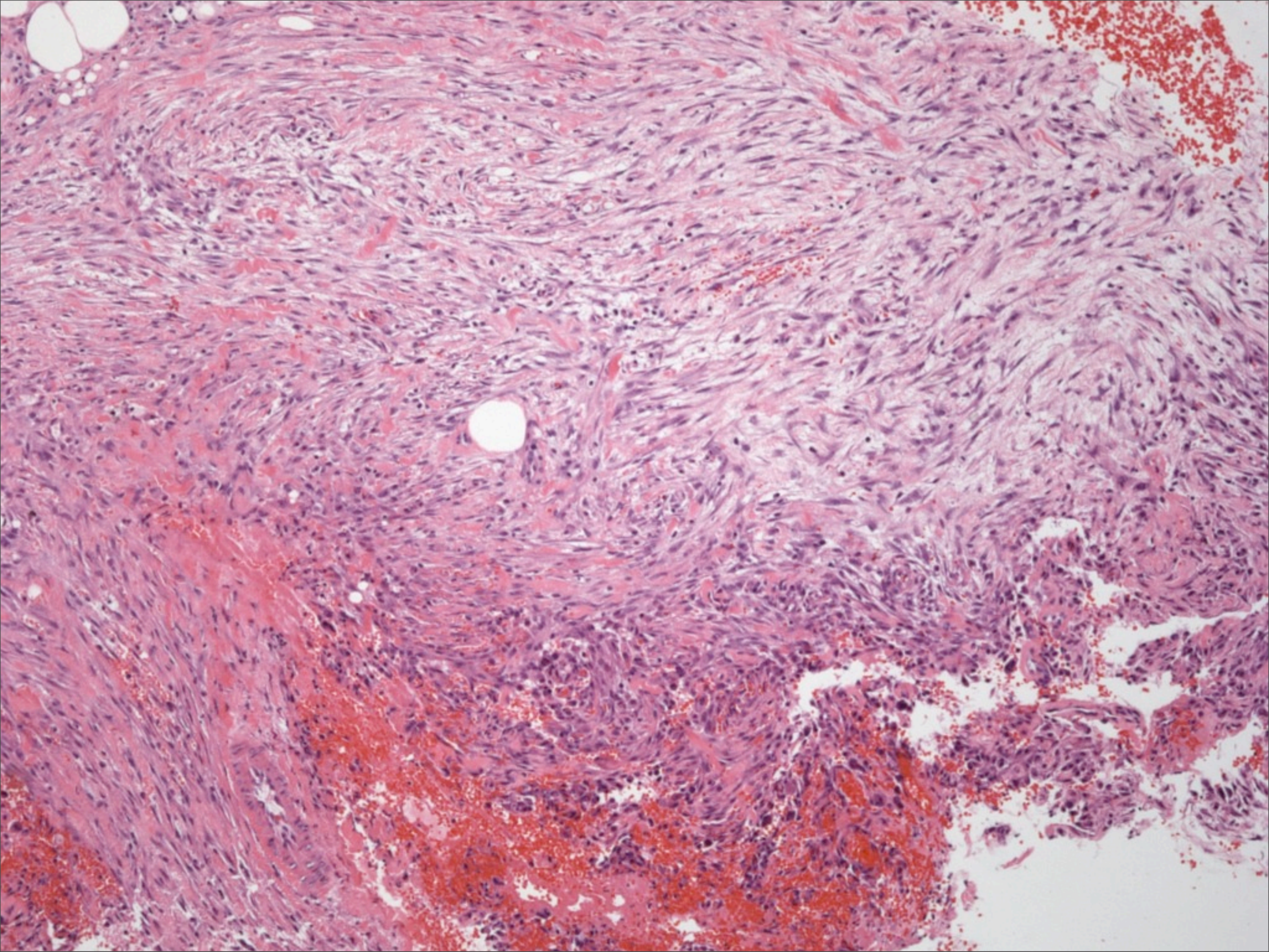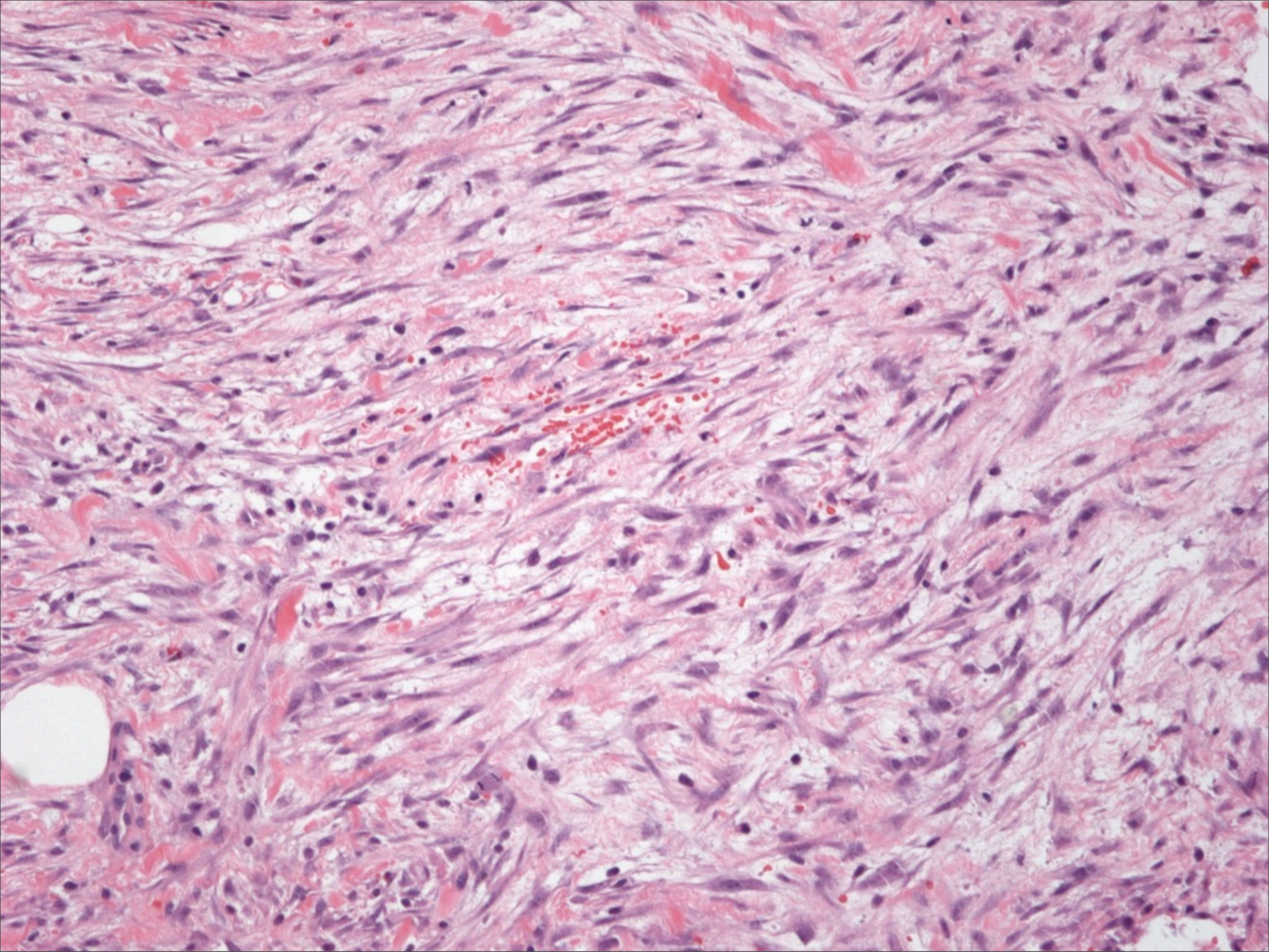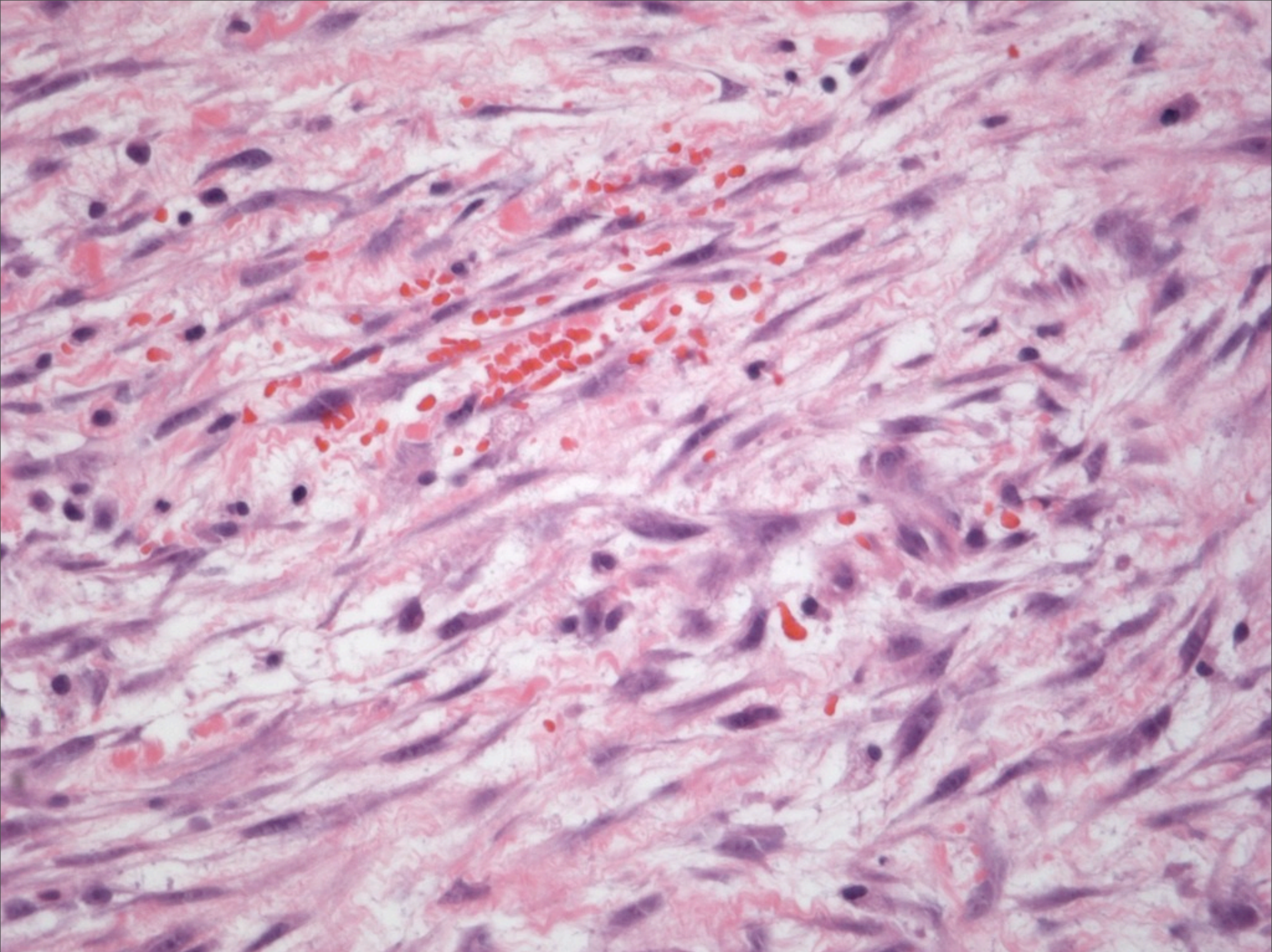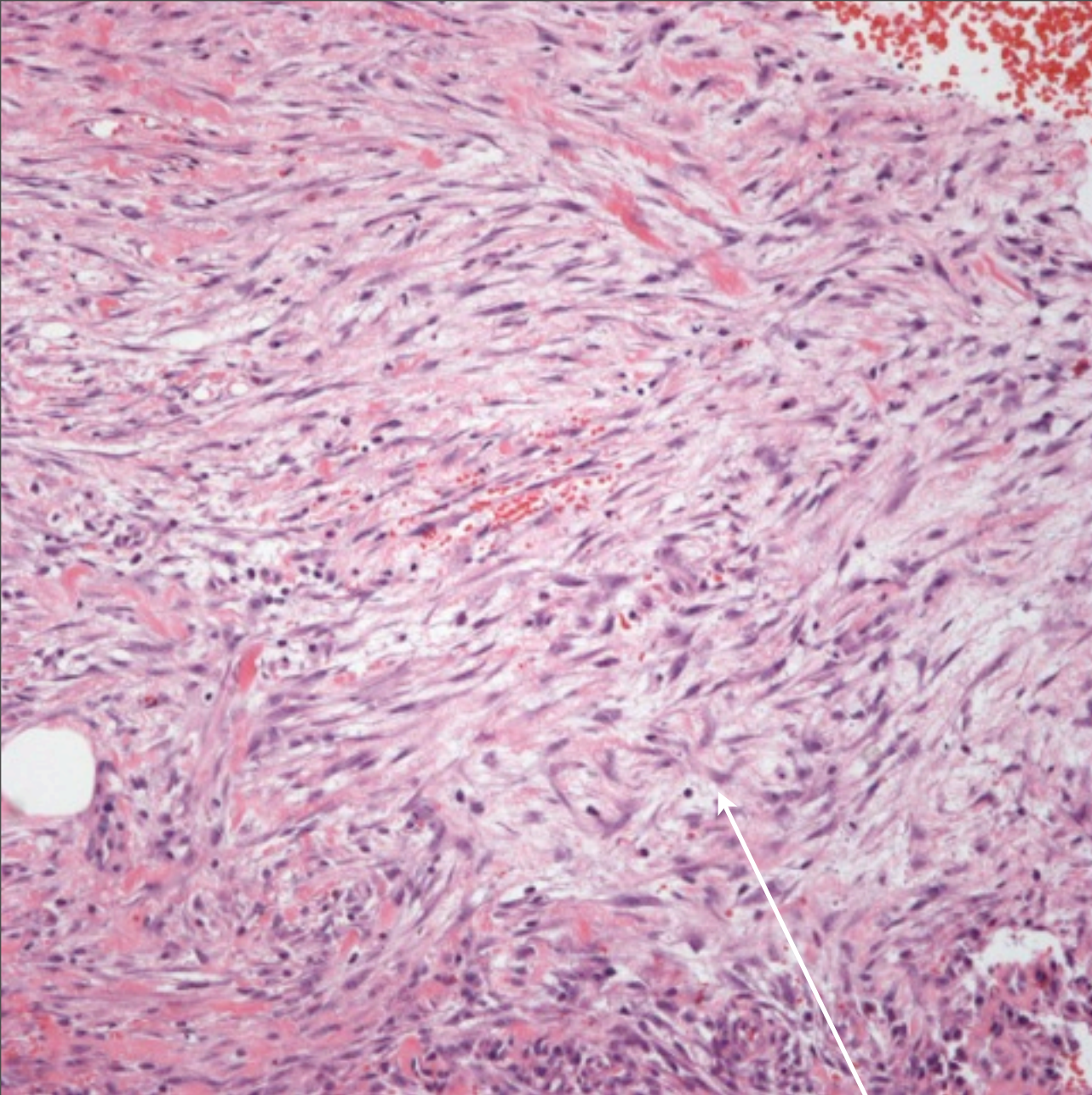


Nodular Fasciitis

Notes

- Nodular fasciitis usually arises as a painful rapidly growing soft tissue tumor in the extremities and may have an antecedent history of trauma
- The characteristic “tissue culture” appearance of the myofibroblasts, brisk mitotic activity, and soft tissue location combined with the clinical history are helpful in arriving at the correct diagnosis



Usually deep soft tissue location

Tissue culture-like appearance of myofibroblasts

Brisk mitotic rate but no atypical mitotic figures

Variable edema and chronic inflammation